

Methods for Minimizing Bleeding in Facelift Surgery: An Evidence-based Review

Ekaterina Tiourin, BS*
Natalie Barton, MD†
Jeffrey E. Janis, MD, FACS‡

Introduction: Bleeding and hematoma remain leading causes of postoperative complications and unsatisfactory patient outcomes in facelift surgery. Several methods have been implemented, and continue to be developed, to minimize bleeding in facelift surgery. These methods include perioperative blood pressure management, compression dressings, drains, tissue sealants, wetting solution infiltrate, and tranexamic acid.

Methods: An evidence-based review of methods used to minimize bleeding in facelift surgery was conducted using the PubMed database according to PRISMA guidelines. Included studies were evaluated for the effects of implemented methods on bleeding outcomes in facelift surgery. Recommendations for each method evaluated were determined based on the amount, level, and heterogeneity of included studies.

Results: Thirty-six studies were included in the evidence-based review. Effective strategies to reduce the time to hemostasis, postoperative drainage volume, and hematoma rate included perioperative blood pressure management, tissue sealants, and tranexamic acid. While the use of drains or wetting solution infiltrate did not demonstrate to significantly influence bleeding outcome measures, these methods may provide other advantages to facelift surgery. Compression dressings have not demonstrated a significant effect on facelift outcome measures.

Conclusions: Perioperative medical management of blood pressure, tissue sealants, and tranexamic acid are most effective in facilitating hemostasis and preventing postoperative hematoma in facelift surgery. (*Plast Reconstr Surg Glob Open* 2021;9:e3765; doi: [10.1097/GOX.0000000000003765](https://doi.org/10.1097/GOX.0000000000003765); Published online 12 August 2021.)

INTRODUCTION

Facelifts are in the top five aesthetic procedures performed in plastic surgery. In 2019, almost 124,000 facelifts were performed in the United States per the American Society of Plastic Surgery.¹ Bleeding and hematomas arise in facelift surgery secondary to disrupted vascular and lymphatic networks as skin flaps are elevated, which may lead to postoperative complications and unsatisfactory patient outcomes.² Hematoma is the most common postoperative complication in facelifts with a reported incidence from 0.2% to 8%.³ The pressure of an expanding hematoma on

the overlying skin flaps may decrease arterial perfusion, cause venous congestion, and increase inflammation that may lead to skin irregularities. While expanding hematomas require immediate re-exploration, minor hematomas of smaller volume may be aspirated. Predisposing risk factors to hematoma in facelift surgery include male gender, history of hypertension, and coagulopathy.⁴ Multiple methods have been developed, and new evidence continues to be generated about how to best manage bleeding in facelifts. This literature review aims to summarize evidence-based methods in minimizing bleeding and postoperative hematoma in facelift surgery.

METHODS

An evidence-based review of methods used to minimize bleeding in facelift surgery was conducted using the PubMed database adhering to PRISMA guidelines (Fig. 1). Inclusion criteria entailed randomized controlled trials, prospective/retrospective cohort and case-control studies, and case series. Exclusion criteria included (1) lack of availability

From the *University of California, Irvine School of Medicine, Irvine, Calif.; †Department of Plastic Surgery, University of California, Irvine Medical Center, Orange, Calif.; and ‡Department of Plastic and Reconstructive Surgery, The Ohio State University Wexner Medical Center, Columbus, Ohio.

Received for publication April 6, 2021; accepted June 24, 2021.

Copyright © 2021 The Authors. Published by Wolters Kluwer Health, Inc. on behalf of The American Society of Plastic Surgeons. This is an open-access article distributed under the terms of the [Creative Commons Attribution-Non Commercial-No Derivatives License 4.0 \(CCBY-NC-ND\)](https://creativecommons.org/licenses/by-nc-nd/4.0/), where it is permissible to download and share the work provided it is properly cited. The work cannot be changed in any way or used commercially without permission from the journal.

DOI: [10.1097/GOX.0000000000003765](https://doi.org/10.1097/GOX.0000000000003765)

Disclosure: Dr. Jeffrey Janis receives royalties from Thieme and Springer Publishing. The other authors listed have no financial interests to declare in relation to the content of this article.

online, (2) no reporting of clinical outcomes, and (3) qualitative analysis with no quantitative evidence. Studies were evaluated for methods implemented in facelift surgery to reduce bleeding, and the effects of these methods on bleeding outcomes. The level of evidence of included studies was determined according to criteria previously reported in plastic surgery literature.⁵ Recommendations for each method were presented depending on the amount, level, and heterogeneity of included studies.

RESULTS

Articles Included

The initial search yielded 493 articles, for which the title and abstract were assessed against the inclusion and exclusion criteria. Of these, 86 articles were fully read to identify the 36 articles to be evaluated in the evidence-based review (Fig. 1). Table 1 details the summary of findings from the included studies for the methods, outcome measures, and recommendation for each strategy to minimize bleeding in facelift surgery.

Perioperative Medical Management

Blood Pressure

The association of elevated blood pressure with increased incidence of hematoma in facelifts has been well

Takeaways

Question: Which methods implemented in facelift surgery influence bleeding outcomes?

Findings: Evidence-based literature review demonstrated that effective strategies to reduce the time to hemostasis, postoperative drainage volume, and hematoma rate include perioperative blood pressure management, tissue sealants, and tranexamic acid. Drains and wetting solution infiltrate did not significantly affect bleeding outcomes but may provide other advantages to facelift surgery. Compression dressings did not significantly influence facelift surgery outcome measures.

Meaning: Perioperative blood pressure management, tissue sealants, and tranexamic acid are the most effective methods implemented in facelift surgery to reduce bleeding.

documented.⁶⁻¹¹ Baker et al demonstrated over a 30-year period a decreased hematoma rate from 8.7% to 3.97% in male facelifts with the implementation of perioperative blood pressure control.³ Ramanadham et al reported a hematoma rate of 0.9% in a study of 1089 facelift patients treated with a perioperative medical regimen aimed to mitigate factors that precipitate elevated blood pressure, such as pain, anxiety, nausea, and exposure to anesthesia.⁹

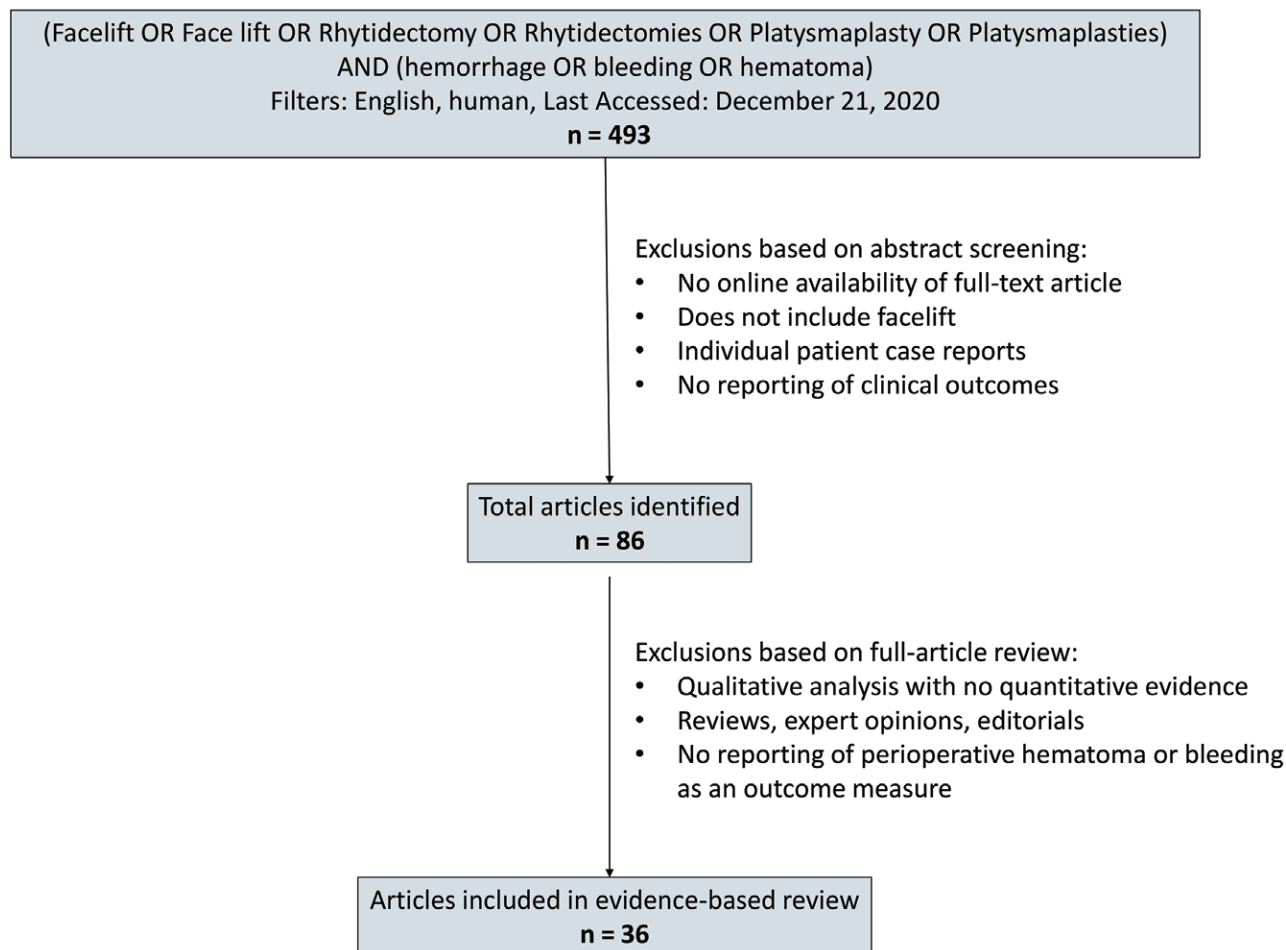


Fig. 1. Flowchart of selection process for articles included in evidence-based review.

Table 1. Summary of Findings and Recommendations for Methods to Minimize Bleeding in Facelifts

Method	Outcome Measure	Effect on Outcome Measure	Level of Evidence of Included Studies*	Heterogeneity of Study Evidence	Strength of Recommendation†
Perioperative blood pressure management	Postoperative hematoma rate	Decrease	Level I/II: 1 Level III: 1 Level IV: 10	Low	Strong
Compression dressings	Postoperative hematoma rate	None	Level I/II: 1 Level III: 0 Level IV: 2	Moderate‡	Weak
Drains	Postoperative hematoma rate	None	Level I/II: 1 Level III: 1 Level IV: 2	Low	Weak
Tissue sealants	Postoperative hematoma rate	Varies: decrease versus none	Level I/II: 9 Level III: 3 Level IV: 0	Moderate§	Moderate
	Postoperative drainage volume	Decrease	Level I/II: 4 Level III: 0 Level IV: 0	Low	Strong
Wetting solution infiltrate	Postoperative hematoma rate	Varies: decrease versus none	Level I/II: 1 Level III: 0 Level IV: 2	High¶	Weak
Tranexamic acid	Postoperative hematoma rate	Decrease	Level I/II: 2 Level III: 0 Level IV: 0	Moderate	Moderate
	Postoperative drainage volume	Decrease	Level I/II: 2 Level III: 0 Level IV: 0	Moderate	Moderate
	Time to hemostasis	Decrease	Level I/II: 1 Level III: 0 Level IV: 0	Moderate	Moderate

* Some studies evaluated multiple methods.

†Strong: many level I-IV evidence support methods have a significant effect on bleeding outcome, low heterogeneity; Moderate: fewer number of level I-IV evidence support methods have a significant effect on bleeding outcome and/or moderate heterogeneity; weak: few or no level I-V evidence support methods have a significant effect on bleeding outcome and/or high heterogeneity.

‡Different types of compression dressings (eg, hiloterapy versus standard).

§ Studies vary in tissue sealant type and whether the effect on hematoma rate reached statistical significance.

¶No effect on postoperative hematoma rate in wetting solution infiltrate containing epinephrine; reduced hematoma rate with wetting solution infiltrate not containing epinephrine.

||Different modes of administration of tranexamic acid (eg, topical, subcutaneous, intravenous).

Medical management to avoid elevated blood pressure in the perioperative period varies by surgeon and anesthesiologist. Although there have been reported medical regimens used in facelifts for blood pressure control,^{9,12} comparative studies between regimens have not been performed. However, there have been studies investigating the incremental influence(s) of single medications. For instance, Beninger et al demonstrated that the addition of 0.1 mg oral clonidine preoperatively had a lower hematoma rate (0% versus 4%, $P < 0.05$) and reduced requirement of antihypertensives postoperatively (4% versus 12%, $P < 0.05$) compared with patients not treated with clonidine.¹³ Moreira et al showed a decrease in hematoma rate in facelift patients treated with oral atenolol in the perioperative period (0% versus 7.4%, $P < 0.001$).¹⁴ These patients also received clonidine along with other anti-hypertensives, as needed. In a 2011 survey of American Society for Aesthetic Plastic Surgery members, Trussler et al reported no medication type in the perioperative period had a correlative effect on hematoma rate in facelifts.¹⁵ The prophylactic delivery of postoperative medications for pain, anxiety, and nausea has been shown to decrease the hematoma rate compared with only giving medications on patient request (0% versus 7%, $P = 0.029$).¹⁶

Studies have reported the association of purposefully medically-induced intraoperative hypotension with

the increased incidence of postoperative hematoma. Intraoperative hypotension may mask areas where hemostasis has not been achieved and where rebound bleeding in the postoperative period may occur as blood pressure rises. Trussler et al reported intraoperative medical treatment to reduce the systolic blood pressure below 100 mm Hg had a greater hematoma rate when compared with medical treatment targeted at blood pressure thresholds higher than 100 mm Hg and below 140 mm Hg (58.7% respondents had a hematoma rate greater than 2 per year versus 38.4% respondents had a hematoma rate less than 2 per year, $P = 0.037$).¹⁵ Rees et al attributed their improved hematoma rate of 1.11% from 3.26% over a 20-year period to avoidance of intraoperative hypotension in facelift patients.¹⁷

Elimination of Dead Space

Compression Dressings

The use of compression dressings is common practice in facelift postoperative care to mitigate the accumulation of fluid collections underneath the skin flaps.¹⁸ In a study of 678 facelifts, there was no difference in hematoma rate between the 331 patients who had standard postoperative compression dressings compared with patients with no postoperative dressings (4.2% versus 4.6%, $P > 0.5$).¹⁹ Alternatives to the standard compression dressing have

been explored in preventing hematoma in facelifts. Jones et al demonstrated that the use of a face mask circulating sterile water cooled to 14°C was not associated with a difference in postoperative hematoma compared with standard dressings ($P = 0.31$ at days 6–8), though it did increase patient-reported swelling ($P = 0.05$ at days 6–8).²⁰ Dressings composed of foam tape and transparent film have also been trialed in facelifts without any incidence of skin complications or hematoma.^{21,22}

Drains

Suction drains are often used postoperatively in facelifts to reduce the incidence of fluid collections leading to complications, such as hematoma, infection, delayed healing, and potential necrosis of the skin flaps. In a study of 678 facelifts, the hematoma rate did not differ between the 449 patients without postoperative drains compared with the 229 patients with drains (4.2% versus 4.8%, $P > 0.4$).¹⁹ Though Perkins et al reported no difference in hematoma rate between patients with or without suction drains in place after facelifts (7% versus 8%, $P > 0.05$), the seroma rate was lower with placement of drains within 24 hours postoperatively (15% versus 37%, $P < 0.01$).² No hematomas developed in any patient in Huang et al's split face study in which each of the 46 patients had one half of the face drained and the other half undrained.²³ Jones et al performed a randomized controlled trial of 50 patients using a split face design where there was no statistically significant difference in hematoma or edema between drained versus undrained sides when performing facelifts with tumescent infiltration ($P = 0.56$; $P = 0.66$).²⁴ The placement of drains led to reduced postoperative ecchymosis clinically (0.92 versus 1.18 on scale 1–4, $P = 0.005$) and subjectively from patient assessment (10% reported more swelling on drained side versus 50% reported more swelling on undrained side, $P = 0.002$). There have also been studies that have reported hematomas upon removal of surgical drains postoperatively in facelift patients.^{8,23}

Tissue Sealants

Proposed benefits of fibrin sealants include decreasing risks for hematoma, seroma, edema, and ecchymosis. These are composed primarily of fibrinogen derived from either autologous or homologous human plasma in combination with thrombin, other clotting factors, antifibrinolytic agents, and calcium chloride. Fibrin sealants facilitate clot formation, which help seal vessels, create adherence, and decrease dead space.²⁵ In facelift surgery, fibrin sealants are typically aerosolized in the subcutaneous plane after soft tissue dissection. Their effectiveness, however, has had mixed reported results. A 2009 meta-analysis of three studies found no statistically significant differences in any outcome measures associated with the use of fibrin sealants in facelifts.²⁶ In 2014, Killion et al published a meta-analysis of seven studies that noted hematoma formation was four times less likely with the use of fibrin sealants in facelifts.^{27–34} A retrospective review of 605 drainless facelifts demonstrated that the use of fibrin sealant in 459

patients reduced the number of minor hematomas (0.4% versus 3.4%, $P = 0.01$), most notably in male patients (1.7% versus 22.2%, $P = 0.01$).³⁵ Several studies reported fibrin sealants did not change hematoma rates in facelifts with drains in place, but they did significantly reduce postoperative drainage volumes.^{33,34,36} Although the use of fibrin sealant in 100 facelifts with drains had no effect on hematoma rate in a 2015 prospective study (1% versus 1%, $P = 1.00$), their use was associated with less hypertrophic scarring and overall postoperative complications, such as necrosis and dehiscence (7% versus 16%, $P = 0.048$).³⁷

An alternative to commercial fibrin sealants is autologous platelet gel. Blood is drawn from the patient undergoing the facelift to extract platelet-rich plasma, which is then combined with calcium chloride and bovine thrombin. Although autologous platelet gel alleviates concerns about potential allergic reactions and theoretical risks of disease transmission with fibrinogen derived from pooled human serum, its use adds time to the surgery and results vary depending on the patient's clotting ability.²⁵ Brown et al reported that the use of autologous platelet gel in 19 facelifts reduced postoperative drainage over 24 hours (78 mL versus 109 mL, $P < 0.02$) with no effect on hematoma rate (0% versus 0%, $P = 1.00$).³⁸

Hemostasis

Wetting Solution Infiltration

The technique of wetting solution infiltration, borrowed from body contouring,^{39,40} has been adapted to facelifts to facilitate surgical dissection and reduce blood loss. The constituents of the wetting solution may vary in concentration, type of local anesthetic and fluid, and the addition of epinephrine and corticosteroid. The volume infiltrated may also affect the degree of skin turgor and blanching. LaTrenta reported that the infiltration of 500 mL of lactated ringer's solution containing 0.3% lidocaine and 1:250,000 epinephrine in 30 facelifts was associated with less operative bleeding compared with 22 controls (10 mL versus 40–50 mL), though no measure of statistical significance was provided.⁴¹ The infiltration of 200 mL of lactated ringer's solution containing 1% lidocaine, 0.25% bupivacaine, 1:200,000 epinephrine, 1.25 mL of 40 mg/mL triamcinolone, and 1500 U of hyaluronidase in 229 facelifts did not influence major or minor hematoma rate compared with 449 retrospective controls (4.8% versus 4.2%, $P > 0.5$; 2.6% versus 2.4%, $P > 0.5$).¹⁹ The wetting solution group, however, had a reduction in wound healing complications, including skin necrosis (0.4% versus 3.1%, $P = 0.03$), alopecia (0.4% versus 4.2%, $P = 0.006$), hypertrophic scarring (0.4% versus 5.6%, $P = 0.001$), stretched scar (0.4% versus 4.7%, $P = 0.003$), and scar revision (0.4% versus 6.5%, $P < 0.001$). In a review of 926 facelifts infiltrating 80–120 mL of solution per side containing 30 mL of 0.5% lidocaine and 1.5 mL of epinephrine (1:1000) mixed in 300 mL of normal saline, there was no difference in hematoma rate compared with controls (0.97% versus 0.61%, $P = 1.00$).⁴² In a multivariate logistic regression analysis, the wetting solution technique

was not related to the incidence of hematoma in facelifts ($P = 0.918$).

There have been conflicting strategies around the use of epinephrine in facelifts, with some concerns around potential rebound bleeding once the vasoconstrictive effect of epinephrine wears off, while others use epinephrine to facilitate hemostasis and to oppose the local vasodilatory effect of lidocaine that may increase edema and postoperative bruising.⁴³ The exclusion of epinephrine from the wetting solution in 232 facelifts compared with 229 controls reduced the incidence of major hematomas (0% versus 4.8%, $P < 0.00001$), minor hematomas (0.4% versus 2.6%, $P = 0.02$), and all types of hematoma combined (0.4% versus 7.4%, $P < 0.01$).¹⁹

Tranexamic Acid

Tranexamic acid (TXA) is an antifibrinolytic agent that has recently gained popularity in facelifts due to its hemostatic and anti-inflammatory properties. By inhibiting the conversion of plasminogen to plasmin in the clotting cascade, TXA prevents enzymatic degradation of fibrin clots and blocks plasmin inflammatory activity.^{44,45} Different applications of TXA have been reported in facelift surgery, including placement of TXA-soaked pledgets under skin flaps, local infiltration, and intravenous administration.⁴⁶ Local infiltration of 1 mg of TXA per 1 mL lidocaine-epinephrine solution subcutaneously reduced time required to achieve hemostasis in 23 facelifts compared with retrospective cases (6.5 min per side versus 20–30 min per side), though no measure of statistical significance was provided.⁴¹ The authors reported the addition of TXA shortened overall operative time as they experienced a drier surgical field that facilitated dissection and closure. There were no hematoma, seroma, or thromboembolic complications in this cohort. Kochuba et al demonstrated no significant differences in the total time to hemostasis on both facelift sides between 22 patients receiving 2 mg of TXA per mL of local infiltrate versus 17 patients receiving 1 mg of TXA per mL of local infiltrate (10.4 minutes versus 15.8 minutes, $P = 0.93$).⁴⁷ Drains were removed in all patients on postoperative day 1 or 2, given minimal output. Although there were no reported hematoma, seroma, or thromboembolic complications, one subject in the 2 mg TXA group experienced skin flap necrosis and one subject in the 1 mg TXA group experienced right marginal mandibular neuropraxia ($P = 1.00$).

The addition of TXA to wetting solution infiltrate has also been investigated. The use of 9.1 mg TXA per 1 mL of wetting solution and local anesthetic in 44 facelifts compared with 32 controls was associated with a reduction in intraoperative blood loss (75% of patients with EBL < 50 mL versus 25% of patients with EBL < 50 mL, $P < 0.001$) and drain output measured postoperatively (14.8 mL versus 50.4 mL, $P < 0.001$).⁴ Drains were able to be removed on the first postoperative day when TXA was administered (77.3% in the TXA group versus 34.4% in the control group, $P < 0.001$).

To assess the effectiveness of intravenous TXA in facelift surgery, Cohen et al performed a randomized, double-blinded study with 27 facelift patients receiving 1 g TXA

intravenously before skin incision and four hours into surgery compared with 17 control patients receiving saline.⁴⁸ Intravenous TXA administration reduced surgeon-rated ecchymosis (1.33 versus 1.63 on scale 1–3, $P = 0.03$) and the incidence of postoperative serosanguinous collections (1% versus 5%, $P < 0.01$). There was no difference in bleeding scores (1.74 versus 1.88 on scale 1–3, $P = 0.54$), patient-rated bruising or edema (1.56 versus 1.73 on scale 1–3, $P = 0.26$; 1.63 versus 1.88 on scale 1–3, $P = 0.15$), or surgeon-rated edema (1.42 versus 1.65 on scale 1–3, $P = 0.12$). Mean patient blood pressure and pulse rate also did not differ between the groups.

DISCUSSION

Evidence-based methods are available to support lower rates of bleeding and ecchymosis in facelift surgery. Studies included in this review reported different measures of bleeding, including postoperative hematoma rate, postoperative drainage volume, and intraoperative time to hemostasis. The evidence most strongly supports perioperative blood pressure control in reducing the risk of postoperative hematoma. The impact of tissue sealants on hematoma rate and postoperative drain outputs varies among studies. This may be due to inconsistencies, such as different volumes of tissue sealant applied, types of tissue sealant utilized, and different study designs. Moreover, tissue sealants may limit the spread of subclinical hematomas that may be difficult to quantify. Although tissue sealants have also been shown to improve postoperative healing with decreased inflammation, ecchymosis, and hypertrophic scarring, they do incur additional costs, dedicated operative time to prepare and administer correctly, theoretical risks for disease transmission from blood-borne products, and potential for allergic reactions. The use of autologous tissue sealant may mitigate concerns for disease transmission and hypersensitivity. Limited evidence demonstrated that the exclusion of epinephrine from infiltrating solution reduced hematoma rate. Risking rebound bleeding associated with epinephrine as its vasoconstrictive effect wears off should be balanced against the unopposed vasodilation incurred by lidocaine in the solution.

Evidence supports the addition of TXA to facelift surgery in reducing overall operative time with improved hemostasis and decreasing postoperative drain output. The low cost and safety profile make TXA a simple addition to consider for facelift surgeries. Further studies are warranted to compare the use of TXA versus epinephrine in local anesthetic solutions to determine which agent better optimizes postoperative outcomes while mitigating risks of rebound bleeding. More studies are also needed to determine the optimal dosing and method of TXA administration in facelift surgery. Subcutaneous infiltration provides a localized, more direct effect compared with topical administration that loses product to gauze or irrigation. It is unclear whether localized versus systemic administration increases the efficacy of TXA in facelifts.

Although the use of wetting solution infiltration or placement of drains have not been demonstrated to significantly influence bleeding outcome measures, these methods

provide other advantages to facelift surgery. Wetting solution infiltration provides greater ease of surgical dissection, less time achieving hemostasis, reduced soft tissue trauma, and reduced intraoperative bleeding. Moreover, while the collective evidence shows the routine use of suction drains does not reduce postoperative hematoma in facelifts, drain care and implementation strategies may vary and influence postoperative outcomes accordingly.⁴⁹ Placement of drains has also demonstrated improvement in postoperative seroma rates and perceived bruising.⁵⁰ This benefit must be weighed against the downsides associated with suction drains. Drains may malfunction with no fail-safe, tend to be uncomfortable to the patient, and can create tracts underneath the skin flaps. Moreover, the removal of drains may provoke bleeding that may also lead to hematoma formation. Studies have also shown that facelifts performed with tissue sealant and no drains were not associated with any increased complication rates. Tissue sealants may therefore obviate the need for drains and their associated disadvantages to postoperative healing.

With no measurable significant effect on hematoma incidence or other outcome measures, postoperative compressive dressings may provide false reassurance to the surgeon in preventing complications in facelifts. Tight, uncomfortable dressings can also be disliked by patients and aggravate postoperative blood pressure, as well as can compromise the skin flap vascularity.^{9,19} The common practice of the postoperative head wrap, only open anteriorly, does not permit visualization of the surgical site should complications arise.²¹ It may be reasonable to place a light, nonrestrictive dressing in the first few postoperative hours to provide support and reassurance,¹⁹ after which direct visualization of the surgical site may allow easier detection of postoperative complications.

CONCLUSIONS

Several effective, evidence-based methods are available to reduce bleeding in facelift surgery. Perioperative medical management of blood pressure, tissue sealants, and tranexamic acid are most effective in facilitating hemostasis and preventing postoperative hematoma. Further studies may consider investigating optimal dosing and administrations of tissue sealants, wetting solution, and tranexamic acid.

Jeffrey E. Janis, MD, FACS

Department of Plastic and Reconstructive Surgery
The Ohio State University Wexner Medical Center
915 Olentangy River Road
Columbus, OH 43212
E-mail: jeffrey.janis@osumc.edu
Twitter: @jjanismd

REFERENCES

1. Plastic Surgery Statistics Report 2019. 2019. Available at <https://www.plasticsurgery.org/documents/News/Statistics/2019/plastic-surgery-statistics-full-report-2019.pdf>. Accessed December 22, 2020.
2. Perkins SW, Williams JD, Macdonald K, et al. Prevention of seromas and hematomas after face-lift surgery with the use of postoperative vacuum drains. *Arch Otolaryngol Head Neck Surg.* 1997;123:743–745.
3. Baker DC, Stefani WA, Chiu ES. Reducing the incidence of hematoma requiring surgical evacuation following male rhytidectomy: A 30-year review of 985 cases. *Plast Reconstr Surg.* 2005;116:1973–85; discussion 1986.
4. Schroeder RJ II, Langsdon PR. Effect of local tranexamic acid on hemostasis in rhytidectomy. *Facial Plast Surg Aesthet Med.* 2020;22:195–199.
5. Rifkin WJ, Yang JH, DeMitchell-Rodriguez E, et al. Levels of evidence in plastic surgery research: A 10-year bibliometric analysis of 18,889 publications from 4 major journals. *Aesthet Surg J.* 2020;40:220–227.
6. Grover R, Jones BM, Waterhouse N. The prevention of haematoma following rhytidectomy: A review of 1078 consecutive face-lifts. *Br J Plast Surg.* 2001;54:481–486.
7. Straith RE, Raju DR, Hipps CJ. The study of hematomas in 500 consecutive face lifts. *Plast Reconstr Surg.* 1977;59:694–698.
8. Berry EP, Frolich SC, Moynahan P. Post-auricular open drainage to reduce postoperative bleeding in rhytidectomy. *Aesthetic Plast Surg.* 1983;7:83–86.
9. Ramanadham SR, Mapula S, Costa C, et al. Evolution of hypertension management in face lifting in 1089 patients: Optimizing safety and outcomes. *Plast Reconstr Surg.* 2015;135:1037–1043.
10. Ramanadham SR, Costa CR, Narasimhan K, et al. Refining the anesthesia management of the face-lift patient: Lessons learned from 1089 consecutive face lifts. *Plast Reconstr Surg.* 2015;135:723–730.
11. Maricevich MA, Adair MJ, Maricevich RL, et al. Facelift complications related to median and peak blood pressure evaluation. *Aesthetic Plast Surg.* 2014;38:641–647.
12. Chung KH, Cho MS, Jin H. Perioperative hypertension management during facelift under local anesthesia with intravenous hypnotics. *Arch Plast Surg.* 2017;44:276–282.
13. Beninger FG, Pritchard SJ. Clonidine in the management of blood pressure during rhytidectomy. *Aesthet Surg J.* 1998;18:89–94.
14. Moreira AC, Moreira M, Gurgel SJ, et al. Atenolol prevents the formation of expansive hematoma after rhytidoplasty. *Rev Col Bras Cir.* 2014;41:305–310.
15. Trussler AP, Hatef DA, Rohrich RJ. Management of hypertension in the facelift patient: Results of a national consensus survey. *Aesthet Surg J.* 2011;31:493–500.
16. Beer GM, Goldscheider E, Weber A, et al. Prevention of acute hematoma after face-lifts. *Aesthetic Plast Surg.* 2010;34:502–507.
17. Rees TD, Barone CM, Valauri FA, et al. Hematomas requiring surgical evacuation following face lift surgery. *Plast Reconstr Surg.* 1994;93:1185–1190.
18. Livermore N, Schoenbrunner AR, Janis JE. A critical examination of the science and role of compression garments in aesthetic surgery. *Plast Reconstr Surg.* Accepted 2020.
19. Jones BM, Grover R. Avoiding hematoma in cervicofacial rhytidectomy: A personal 8-year quest. Reviewing 910 patients. *Plast Reconstr Surg.* 2004;113:381–387; discussion 388–390.
20. Jones BM, Grover R, Southwell-Keely JP. Post-operative hiloterapy in SMAS-based facelift surgery: A prospective, randomised, controlled trial. *J Plast Reconstr Aesthet Surg.* 2011;64:1132–1137.
21. Basile AR, Basile FV. Transparent dressing for rhytidectomy. *Aesthetic Plast Surg.* 2001;25:454–456.
22. Teimourian B, Mankani M, Stefan M. A new dressing technique to minimize ecchymoses following face lifts. *Plast Reconstr Surg.* 1995;96:222–223.
23. Huang TT, Blackwell SJ, Lewis SR. Routine use of a suction drain in facial rhytidoplasty. *Ann Plast Surg.* 1987;18:30–33.
24. Jones BM, Grover R, Hamilton S. The efficacy of surgical drainage in cervicofacial rhytidectomy: A prospective, randomized, controlled trial. *Plast Reconstr Surg.* 2007;120:263–270.

25. Toriumi DM, Chung VK, Cappelle QM. Surgical adhesives in facial plastic surgery. *Otolaryngol Clin North Am.* 2016;49:585–599.
26. Por YC, Shi L, Samuel M, et al. Use of tissue sealants in face-lifts: A metaanalysis. *Aesthetic Plast Surg.* 2009;33:336–339.
27. Killion EA, Hyman CH, Hatef DA, et al. A systematic examination of the effect of tissue glues on rhytidectomy complications. *Aesthet Surg J.* 2015;35:229–234.
28. Fezza JP, Cartwright M, Mack W, et al. The use of aerosolized fibrin glue in face-lift surgery. *Plast Reconstr Surg.* 2002;110:658–64; discussion 665.
29. Lee S, Pham AM, Pryor SG, et al. Efficacy of Crosseal fibrin sealant (human) in rhytidectomy. *Arch Facial Plast Surg.* 2009;11:29–33.
30. Kamer FM, Nguyen DB. Experience with fibrin glue in rhytidectomy. *Plast Reconstr Surg.* 2007;120:1045–1051.
31. Marchac D, Sándor G. Face lifts and sprayed fibrin glue: An outcome analysis of 200 patients. *Br J Plast Surg.* 1994;47:306–309.
32. Marchac D, Greensmith AL. Early postoperative efficacy of fibrin glue in face lifts: A prospective randomized trial. *Plast Reconstr Surg.* 2005;115:911–6; discussion 917.
33. Hester TR Jr, Gerut ZE, Shire JR, et al. Exploratory, randomized, controlled, phase 2 study to evaluate the safety and efficacy of adjuvant fibrin sealant VH S/D 4 S-Apr (ARTISS) in patients undergoing rhytidectomy. *Aesthet Surg J.* 2013;33:323–333.
34. Hester TR Jr, Shire JR, Nguyen DB, et al. Randomized, controlled, phase 3 study to evaluate the safety and efficacy of fibrin sealant VH S/D 4 s-apr (Artiss) to improve tissue adherence in subjects undergoing rhytidectomy. *Aesthet Surg J.* 2013;33:487–496.
35. Zoumalan R, Rizk SS. Hematoma rates in drainless deep-plane face-lift surgery with and without the use of fibrin glue. *Arch Facial Plast Surg.* 2008;10:103–107.
36. Oliver DW, Hamilton SA, Figle AA, et al. A prospective, randomized, double-blind trial of the use of fibrin sealant for face lifts. *Plast Reconstr Surg.* 2001;108:2101–5, discussion 2106.
37. Berry MG, Stanek JJ. Fibrin tissue adhesive for face- and necklift. *J Plast Reconstr Aesthet Surg.* 2015;68:1325–1331.
38. Brown SA, Appelt EA, Lipschitz A, et al. Platelet gel sealant use in rhytidectomy. *Plast Reconstr Surg.* 2006;118:1019–1025.
39. Kenkel JM, Rohrich RJ, Janis JE. Liposuction. In: *The Art of Aesthetic Surgery: A Clinical Atlas.* 1st ed. St. Louis, Mo: Quality Medical Publishing, Inc.; 2005.
40. Rohrich RJ, Kenkel JM, Janis JE, et al. An update on the role of subcutaneous infiltration in suction-assisted lipoplasty. *Plast Reconstr Surg.* 2003;111:926–927; discussion 928.
41. Latrenta GS. Tumescence cervicofacial rhytidectomy. *Aesthet Surg J.* 1998;18:423–430.
42. Costa CR, Ramanadham SR, O'Reilly E, et al. The role of the superwet technique in face lift: An analysis of 1089 patients over 23 years. *Plast Reconstr Surg.* 2015;135:1566–1572.
43. Swanson E. Evaluation of face lift skin perfusion and epinephrine effect using laser fluorescence imaging. *Plast Reconstr Surg Glob Open.* 2015;3:e484.
44. Couto RA, Charafeddine A, Sinclair NR, et al. Local infiltration of tranexamic acid with local anesthetic reduces intraoperative facelift bleeding: A preliminary report. *Aesthet Surg J.* 2020;40:587–593.
45. Rohrich RJ, Cho MJ. The role of tranexamic acid in plastic surgery: Review and technical considerations. *Plast Reconstr Surg.* 2018;141:507–515.
46. Butz DR, Geldner PD. The use of tranexamic acid in rhytidectomy patients. *Plast Reconstr Surg Glob Open.* 2016;4:e716.
47. Kochuba AL, Coombs DM, Kwiecien GJ, et al. Prospective study assessing the effect of local infiltration of tranexamic acid on facelift bleeding. *Aesthet Surg J.* 2020;41:391–397.
48. Cohen JC, Glasgold RA, Alloju LM, et al. Effects of intravenous tranexamic acid during rhytidectomy: A randomized, controlled, double-blind pilot study. *Aesthet Surg J.* 2020;41:155–160.
49. Khansa I, Khansa L, Meyerson J, et al. Optimal use of surgical drains: Evidence-based strategies. *Plast Reconstr Surg.* 2018;141:1542–1549.
50. Janis JE, Khansa L, Khansa I. Strategies for postoperative seroma prevention: A systematic review. *Plast Reconstr Surg.* 2016;138:240–252.